

Lab: Frog Dissection

Introduction:

Frogs belong to the class Amphibia. Amphibians have adaptations for living in terrestrial as well as aquatic environments. Frogs are among the most commonly studied organisms in biology. Although many differences exist between humans and frogs, the basic body plans are similar. Humans and frogs both belong to the phylum Chordata. By studying the anatomy of the frog, you will be better able to understand your own body.

In this investigation you will observe the external features of a preserved frog and identify parts of its external anatomy. You will also dissect the preserved frog to observe its internal anatomy and make comparisons to human anatomy.

Pre-Lab Questions:

Read the entire investigation. Then answer the following questions.

1. Define the following terms related to the positioning of the frog.
 - a. Dorsal: _____
 - b. Ventral: _____
 - c. Anterior: _____
 - d. Posterior: _____

2. Why is it important to check-off each step of this laboratory procedure before continuing to the next step?

3. What will you examine in **Part A** of this investigation?

4. Why is it important to make shallow cuts when cutting the skin around the frog's hindlimb?

5. After you expose the internal organs in **Part B**, what two structures might you have to remove in order to examine the organs?

6. Which organs of the digestive system will you identify in **Part B**?

7. Without the presence of eggs, how will you know whether your frog is male or female?

Materials (per group):

Preserved frog, forceps, paper towels, plastic food bag, dissecting tray, dissecting pins, dissecting scissors, dissecting probes, waterproof marker, eye dropper

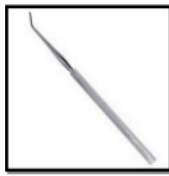Scissors



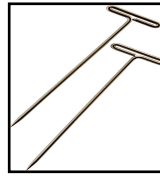
Forceps



Probe



Pins



Dissecting Tray



Safety:

Put on disposable plastic gloves. Treat the preserved animal, preservations solution, and all the equipment that touches the organism as potential hazards. Do not touch your eyes or your mouth with your hands. Be careful when handling sharp instruments. Always cut away from your body and away from others. Return or dispose of all materials according to the instructions of your teacher. Wash your hands with soap and warm water after carrying out this investigation.

PART A: External Anatomy of the Frog

1. Obtain a preserved frog. Rinse the frog with water to remove excess preservative. **CAUTION:** The preservative used on the frog can irritate your skin. Avoid touching your eyes while working with the frog. Dry the frog with paper towels and place it in a dissecting tray.
2. Identify the *dorsal* and *ventral* surfaces and the *anterior* and *posterior* ends of the frog. **Notice the color on each surface of the frog.**
3. Locate the *forelegs* and the *hindlegs*. Each foreleg, or arm, is divided into four regions: *upper arm*, *forearm*, *wrist*, and *hand*. Each hindleg also has four regions: *thigh*, *lower leg*, *ankle*, and *foot*. Identify the parts of the forelegs and hindlegs. Examine the hands and feet of the frog. If the hands have enlarged thumbs, the frog is male. **How many digits are on each hand and foot? Is your frog a male or female?**
4. Locate the two large, protruding eyes. Lift the outer eyelid using a probe. Beneath the outer lid is an inner lid called the *nictitating membrane*.
5. Posterior to each eye is a circular region of tightly stretched skin. This region is the *tympanic membrane*, or eardrum. Locate the tympanic membranes on both sides of the head.
6. Anterior to the eyes, locate two openings called the *external nares* (singular, *nares*), or nostrils.
7. Hold the frog firmly in the dissecting tray. Using scissors, make a small cut at each of the hinged points of the jaw. **CAUTION:** *To avoid injury, cut in a direction away from your hands and body.* Open the mouth as much as possible. Under running water, rinse away any excess preservative.

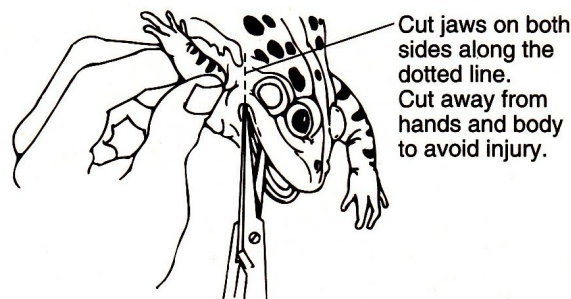


Figure 1

8. The tongue is the most noticeable structure in the mouth. Observe where the tongue is attached and note the two projections at the free end.
9. At the back of the mouth, locate the large horizontal opening, the *gullet opening*. In front of the gullet opening, find a *vertical slit*, and the *glottis*.
10. Look for two openings on the backsides of the floor of the mouth. These are the openings to the vocal sacs. They are present in male frogs but not in female frogs.
11. Examine the roof of the mouth. Near the front center of the roof of the mouth are two small bumps. These bumps are the *vomerine teeth*. On either side of the vomerine teeth are the openings of the *internal nares*. Behind the vomerine teeth, observe two large bulges. These bulges are the *eye sockets*. Run your finger along the top jaw. The teeth you feel are the *maxillary teeth*. The openings of the *Eustachian tubes* are on either side near the back of the mouth. Insert a probe into an opening of one Eustachian tube. Note where the probe stops.

PART B: Internal Anatomy of the Frog

1. Place your preserved frog in a dissecting tray with the ventral surface up. With dissecting pins, securely pin the frog's feet and hands to the bottom of the dissecting tray. Angle the pins away from the body of the frog so that they will not interfere with your dissection.

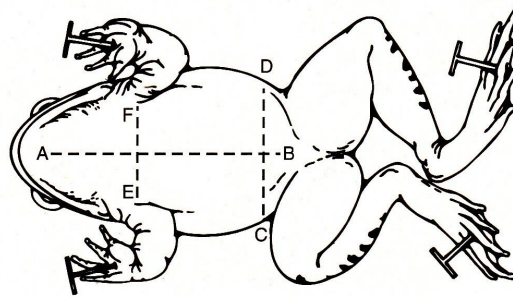


Figure 2

2. With forceps, lift the loose skin of the abdomen. Carefully insert the tip of a pair of scissors beneath the skin. **CAUTION: To avoid cutting yourself, cut in a direction away from your hands and body.** Cut the skin along line AB as show in Figure 2. Using forceps and scissors, continue cutting skin along lines CD and EF.
3. With your fingers, carefully separate the skin from the underlying muscles. Open the flaps of skin as far back as possible and pin them to the bottom of the dissecting tray. Angle the pins away from the body of the frog so that they will not interfere with your dissection. Notice the blood vessels branching throughout the inner lining of the skin. Observe the abdominal and pectoral muscles. Note the direction of the muscle fibers.
4. Carefully lift the abdominal muscles with the forceps. Cut a second AB incision. **Note: Keep the cut through the muscles shallow so as not to damage underlying organs.** As the incision is made in the chest, or pectoral area, you will need to cut through bone. This bone is part of the pectoral girdle. **Note: Use extra force with the scissors when cutting through the bone. Be careful not to damage any of the internal organs below the bone.** Make cuts CD and EF through the abdominal muscle.
5. Remove the pins holding the skin in place. Stretch the abdominal opening as much as possible. At this time the hands and feet of the frog may need to be repinned.
6. Study the positions of the exposed organs. Notice that most of the organs are held in place by thin, transparent tissues called *mesenteries*.

7. If the frog is a mature female, the most obvious organs will be the ovaries. The *ovaries* are white sacs swollen with tiny black-and-white eggs. Carefully lift the ovaries from the body cavity, cut the attachments with scissors, and remove the ovaries from the frog. **Note: Be careful not to rupture the ovaries with scissors. If the ovaries are ruptured, the eggs inside can spill out.**
8. The large reddish-brown organ in the upper part of the abdominal cavity is the *liver*. **How many lobes does the liver contain?**
9. With your fingers or a probe, lift and separate the lobes of the liver upward. Behind the middle lobe, look for a greenish, finger-shaped gland. This gland is the *gallbladder*. You may be able to locate the *bile duct* leading from the liver to the gallbladder.
10. With scissors, carefully remove the liver and gallbladder from the body. The remaining organs of the digestive system are easier to see with the liver removed.

DIGESTIVE SYSTEM

11. Locate the *esophagus*, which is a white tube leading from the mouth and connecting to the upper part of the white, muscular *stomach*. Notice the shape of the stomach. Look for a constriction at the lowest part of the stomach. This constriction is the *pylorus*. The pylorus leads into the long, coiled *small intestine*. Pull the loops of small intestine away from the body. Notice the *mesentery* that holds the intestines in place. Inside the first loop of the small intestine near the stomach, locate a thin, white organ called the *pancreas*. Also in the intestinal mesentery, locate a brown bean-shaped organ called the *spleen*. The spleen is an organ of the circulatory system.
12. The small intestine ends in a large bag-shaped organ, the *large intestine*. The last organ of the digestive system is the *cloaca*, a saclike organ at the end of the large intestine. Undigested food leaves the frog's body through an opening called the *anus*.
13. With scissors, cut the esophagus near the stomach. Cut through the large intestine just above the cloaca. With your fingers, carefully remove the digestive system from the body.
14. Stretch out the digestive system on the dissecting tray. With scissors, cut open the stomach along its outside curve. Open the stomach and examine its structure and contents. **Observe the inside of the stomach. Describe the content's of the frog's stomach.**
15. Dispose of the digestive system, liver, and ovaries according to your teacher's instructions.

UROGENITAL SYSTEM

16. The reproductive system and urinary system of the frog are closely connected and can be studied as the combine urogenital system. The two *kidneys* are reddish-brown organs located on the dorsal posterial wall of the abdominal cavity. The kidneys lie on either side of the backbone. **Note: The kidneys may be covered with a thin membrane. If so, carefully tear open the membrane with the point of a dissecting needle.** The yellow, fingerlike lobes attached to the kidneys are *fat bodies*. A small, twisted tube called the *ureter* leads from each kidney into the saclike *urinary bladder*. The bladder is connected to the *cloaca*.
17. Locate the reproductive organs of the frog. If your frog is a male, it possesses *testes*, tiny white or yellow oval organs found on the ventral surface of the kidneys.
18. If your frog is a female, it possessed egg-filled *ovaries* that were removed in step 7. If your frog is an immature female, the pale oval ovaries are located ventral to the kidneys. Leading from each ovary is a long coiled tube called the *oviduct*. The oviduct extends along the side of the body cavity. The oviduct eventually joins the *cloaca*.

RESPIRATORY SYSTEM

19. Locate the two *lungs*. They are small, spongy brown sacs that lie to the right and left of the heart. Look for the *bronchial tubes* that extend from the anterior part of the lungs and join with the *trachea*, or windpipe.
20. Insert a dropper into the glottis of the frog. Pump air into the lungs and **observe what happens**.
21. With scissors and forceps, carefully remove the lungs from the frog's body. Dispose of the lungs according to your teacher's instructions.

CIRCULATORY SYSTEM

22. Locate the *heart*. The heart is encased in a membranous sac called the *pericardium*. With the tip of the scissors, carefully cut open the pericardium.
23. Note the vessels attached to the heart. The large artery on the ventral surface of the heart is the *coronary artery*. **Note: If the frog has been injected with red and blue latex paint, the veins and arteries will be obvious.**
24. Carefully cut the blood vessels leading to and from the heart. Remove the heart from the frog. Place the heart in the dissecting tray with the dorsal surface facing up. Identify the right and left atria and the ventricle. Touch and compare the walls of the two atria and the ventricle.
25. Observe the dorsal surface of the heart. Locate the thin-walled triangular sac called the *sinus venosus*. Locate the two veins leading from the top and the one vein leading from the bottom of the sinus venosus.
26. With the scalpel, cut the heart into anterior and posterior halves. Note the thickness of the walls and the types of heart chambers. **CAUTION: Be careful when using a scalpel. Always cut in a direction away from your hands and body.**

MUSCULAR SYSTEM

27. Remove the pins from the frog's feet and hands.
28. Cut the skin completely around the upper thigh of one leg, as if cutting off the leg of a pair of pants. With forceps, carefully pull the skin downward to the foot. Expose the thigh muscles, the knee, and the calf muscles.
29. Move the lower leg up and down to stimulate the lift movement during a jump. Observe the various leg muscles involved in the leg movement.
30. Follow your teacher's instructions for storing the frog for further use or properly disposing of the frog and its parts. Thoroughly wash, dry, and put away your dissecting tray and tools. Wash your hands with soap and water.